

Original Article

Female Genital Rejuvenation Surgery: A Study of 34 Cases.

Imran Choudhury¹, Sayeed Ahmed Siddiky², Dr. Tajkera Sultana Chowdhury³, Dr Sattar Mohammad Sumon⁴, Farhana Alam⁵

Abstract:

Female genital rejuvenation surgery is a rapidly growing sub-specialty in the world. There is also a steady rise in demand for these procedures in Bangladesh. In our series variety of procedures were performed on 34 patients from January 2017 to June 2021 labiaplasty was mostly performed cosmetic procedure and the indication of vaginoplasty was more to improve sexual function. Most of the procedures were done as a day case surgery or with a minimal hospital stay. A combination of procedures to address individual components leads to a better cosmetic and functional outcome.

Keywords: Genital Rejuvenation Surgery, labiaplasty, Minimal hospital stay

Introduction:

Aesthetics is what has been used in literature or in many scientific papers thousand times more for women than men. As a whole cosmetic surgery is already well popularized among the ladies around the globe irrespective of age, ethnicity and religion¹. Female aesthetic genital surgery is now also a point of interest among our population and a rapidly growing sub-specialty in the globe as well.

A variety of surgical, non-surgical or combined procedures that include Labiaplasty, Vaginoplasty, Hymenoplasty, Perineoplasty, Pubic enhancement etc are well popularized now a days. However, at present we will consider the surgical procedures only. We believe that these interventions provide psychological and functional improvement in sexual stimulation and satisfaction.

Materials and methods

A variety of procedures were performed on 34 patients from July 2016 to September 2021 which are as follows, labiaplasty, vaginoplasty, hymenoplasty, and perineoplasty. These were performed either in isolation or as a combo procedure. Patients were from different age group ranges from 21-50 years of age.

Table 1: The demography according to age

Age group (years)	No. of patients	%
21-30	3 (8.8)	
31-40	23 (67.6)	
41-50	8 (23.5)	

1. Dr. Imran Choudhury MBBS, FCPS, Associate Professor, Burn and Plastic Surgery department, Anwer Khan Modern Medical College Hospital, Dhaka.

2. Dr. Sayeed Ahmed Siddiky, FCPS, FRCS, FACS. Consultant Plastic & Aesthetic Surgeon, Institute:Cosmetic Surgery Centre Ltd. & Bangladesh Specialized Hospital Ltd. Dhaka

3. Dr. Tajkera Sultana Chowdhury FCPS, MS, Assistant Professor, Urology department, Shaheed Suhrawardi Medical College Hospital, Dhaka.

4. Dr Sattar Mohammad Sumon , Associate professor, Department of plastic and reconstructive surgery, Monowara Sikder medical college, soriyotpur,

5. Farhana Alam, SMO (Department of paediatrics), Dhaka National Medical Institute Hospital, Dhaka

Correspondence to:

Dr. Imran Choudhury MBBS, FCPS, Associate Professor, Burn and Plastic Surgery department, Anwer Khan Modern Medical College Hospital, Dhaka. Phone: +8801819126228, email: drimran73@yahoo.com

During their first consultation patient's desire was noted. A detail Uro-Gynaecological history was also recorded. After proper physical examination, planned procedures and their possible complications were discussed in detail with the patient.

A detail record of post-operative recovery and any complications was also observed.

Table 2: Distribution of number of patients underwent different procedures

Procedures	No. of patients %
Hymenoplasty	3 (6.1)
Labioplasty	15 (30.6)
Vaginoplasty	17 (34.7)
Perineoplasty	3 (6.1)
Vaginoplasty with Perineoplasty	3 (6.1)
Vaginoplasty with LP	3 (6.1)
Pubic enhancement	5(10.2)
Different surgical techniques	49 Procedures

Labioplasty

It refers to a reduction of labia minora by excision of excess tissue and the cut edges are then sutured together with absorbable suture usually in a running technique. While performing this it should be kept in mind to limit the amputation level to a minimal width of at least 1 cm. if it is performed with a smaller minimal width can result in aesthetically unpleasant scarring too close to the introitus causing sensory impairment, chronic pain and dyspareunia².

Reduction of labia majora is done either due to primary hypertrophy (volume excess) or due to secondary excess skin (volume loss). In case of volume excess liposuction and wedge excision for excess skin is practiced. In certain situation both the procedures needed to be done simultaneously.

Hymenoplasty

It is usually performed by freshening the edges and approximation of the hymenal membrane with absorbable interrupted suture to narrow the vaginal orifice³.

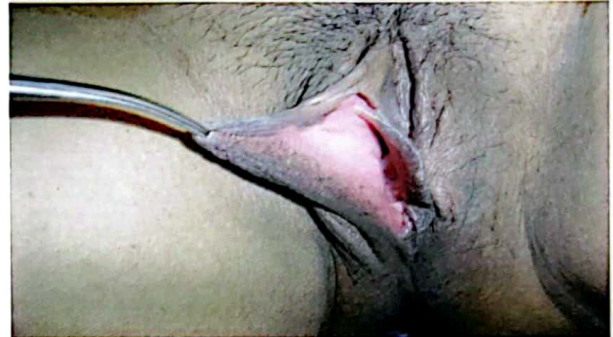

Fig 1: Prominent labia minora

Vaginoplasty

The goal of this procedure is to reconstruct the lower third of vagina. In this procedure a portion of mucosa is excised from vaginal fornices surgically to tighten the lower third⁴.

Perineoplasty

It involves surgical reconstruction of the vaginal introitus usually with low posterior compartment repair and approximation of the levatorani muscle. A diamond-shaped wedge of tissue is removed and approximation of the levatorani muscles causes an elevated perineum and strengthened perineal body resulting in an improved sexual function⁵.

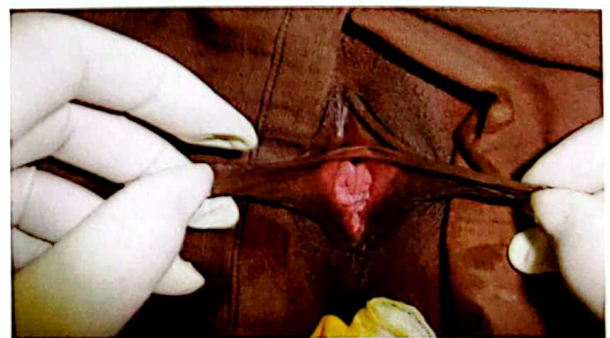


Fig 2: Before and after labioplasty

Pubic enhancement

It includes pubic lifting and pubic liposuction. In case of pubic lifting, reduction of the mons pubis for ptosis and excess tissue in this area usually done by wedge excision in a transverse direction. This procedure can also be done combined with abdominoplasty. Pubic liposuction is effective in patients without skin excess ⁶.

Table 3: Post-operative complications

Complication	No. of patients %
Bleeding	0
Hematoma	0
Wound dehiscence	13.7
Scarring	0
Dyspareunia	27.4
Reduced sensation	0

Results

Every patient was asked about their desired outcome at the post-operative follow up visit to grade as “very satisfied”, “satisfied” and “not satisfied”.

Table 4: Patient satisfaction grading

Patient satisfaction grading	No. of patients	No. of patients %
Very satisfied	17	62.96
Satisfied	9	33.33
Not satisfied	1	3.7

Discussion

Aesthetic surgery of female genitalia is now a commonly discussed topic in media as well as in scientific journals. Successful interventions have further contributed to an increase in demand for this sub-specialty. Since female genital rejuvenation surgery became a common plastic surgeon's job, questions have been raised regarding different techniques, indications and

ethics. There are no absolute contraindications although current gynecological disease, sexual dysfunction, unrealistic expectations and smoking are some relative issues ⁷.

In our studies, majority of the patients ranged from 31-40 years (Table 1). This age group is sexually active and more aware about their body changes. This reminds us that we are living in a global village and an easy communication system have made our patients think like some other parts of the world.

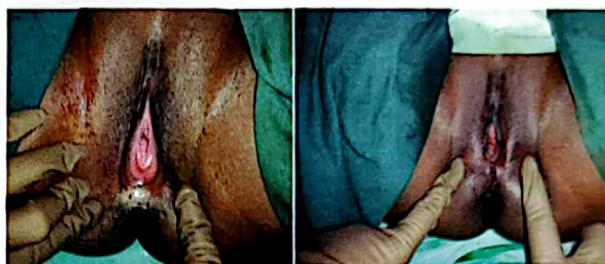

Fig 3: Before and after Perineoplasty

Patients underwent hymenoplasty in our series were very satisfied. With the result. All of them desired a revirgination prior to their marriage. The absence of hymen is not an absolute sign of lost virginity, and the same is true for bleeding at first intercourse. A recent study revealed that hymen was intact in 52% of adolescent girls who admitted to have had sexual intercourse. The hymen is a relatively bloodless membrane and it is unlikely to bleed significantly even if it is torn. Violent penile penetration can result in minor laceration of the vaginal wall that appears to be responsible for “blood-stained bedsheet” ⁸.

In our series second highest number of patients demanded for labioplasty. Rouzier et al reported in 2000 on 163 patients who received a labioplasty and the primary reason was aesthetic dissatisfaction ⁹. The vulvar epithelium of labia minora is highly innervated and sensitive. Incision to any part of the genitalia could compromise this sensitivity and its sexual importance. Neuroma

like hypersensitivity has also been reported after surgery in some literature ¹⁰.

Highest number of patients in our series desired for vaginoplasty and it was also done in combination with other procedures. During life a good number of women complaints of decreased vaginal sensation, most commonly with a feeling of a widened vagina. In a non-erotic setting, Schultz et al. used an electric shock to test the vaginal sensitivity of 60 participants. They concluded that the decreased vaginal sensation must come from a widened vagina causing less friction ¹¹. Vaginal rejuvenation surgery has been practiced since the mid-fifties, where the gynecologist used to tighten the entrance of the organ with an extra stitch while repairing vaginal and perineal tear or episiotomies after giving birth. At that time, it was named as the “husband’s stitch”, “husband’s knot”, or “vaginal tuck” and doctors specifically referred to this procedure as “improving a woman’s well-being” ¹².

Post-operatively one patient of labioplasty had wound dehiscence had to put few secondary stitches. Dyspareunia was a complaint of two patients in the post-operative period underwent vaginal rejuvenation. This problem was resolved with vaginal stretching exercise and use of lubrication during coitus.

Non-surgical techniques such as Radiofrequency and Lasers have been reported in some literature to be effective in vaginal rejuvenation ¹³.

We would like to share that a combination of procedures to improve individual component is better than an isolated surgery and leads to a better aesthetic and functional outcome.

Conclusion

It is difficult to draw a line between medically indicated procedures such as vaginal or pelvic reconstructive surgery & elective surgeries such

as vaginoplasty & labioplasty. Nowadays both function & beauty are addressed together not as individual. To achieve maximum patient satisfaction and minimal complications, involvement of an experienced, trained surgeon is mandatory. Every surgeon should inform patient about various options, perform psychological evaluation and discuss realistic expectations. The surgeon’s skill and comfort level with different techniques must be considered fully. More academic training in this field of aesthetic surgery has now become essential, to ensure proper selection of patients along with better safety of genital aesthetic procedures.

References:

1. Desai SA, Dixit VV. Audit of female genital aesthetic surgery: changing trends in India. *The Journal of Obstetrics and Gynecology of India*. 2018 Jun;68(3):214-20.
2. Dobbela JM, Van Landuyt K, Monstrey SJ. Aesthetic surgery of the female genitalia. In *Seminars in plastic surgery* 2011 May (Vol. 25, No. 02, pp. 130-141). © Thieme Medical Publishers.
3. Goodman MP. Female genital cosmetic and plastic surgery: a review. *The journal of sexual medicine*. 2011 Jun 1;8(6):1813-25.
4. Goodman MP. Female cosmetic genital surgery. *Obstetrics & gynecology*. 2009 Jan 1;113(1):154-9.
5. Goodman MP, Placik OJ, Benson III RH, Miklos JR, Moore RD, Jason RA, Matlock DL, Simopoulos AF, Stern BH, Stanton RA, Kolb SE. A large multicenter outcome study of female genital plastic surgery. *The journal of sexual medicine*. 2010 Apr 1;7(4):1565-77.
6. Kolb S. Available at: Plastikos Surgery Centre, Atlanta. Aesthetic female genital surgery: expanding your practice.
7. Davison S, West J. Available at: Labiaplasty and labia minora reduction. Accessed Feb. 8, 2010. <http://emedicine.medscape.com/article/1372175-overview>
8. Raveenthiran V. Surgery of the hymen: from myth to modernisation. *The Indian journal of surgery*. 2009 Aug;71(4):224.
9. Miklos JR, Moore RD. Labiaplasty of the labia minora: patients’ indications for pursuing surgery. *The journal of sexual medicine*. 2008 Jun;5(6):1492-5.
10. Lloyd J, Crouch NS, Minto CL, Liao LM, Creighton SM. Female genital appearance: ‘normality’ unfolds. *BJOG: An International Journal of Obstetrics & Gynaecology*. 2005 May;112(5):643-6.

11. Weijmar Schultz WC, Van de Wiel HB, Klatter JA, Sturm BE, Nauta J. Vaginal sensitivity to electric stimuli: theoretical and practical implications. *Archives of sexual behavior*. 1989 Apr;18(2):87-95.
12. Green FJ. From clitoridectomies to 'designer vaginas': The medical construction of heteronormative female bodies and sexuality through female genital cutting. *Sexualities, Evolution & Gender*. 2005 Aug 1;7(2):153-87.
13. Karcher C, Sadick N. Vaginal rejuvenation using energy-based devices. *International Journal of Women's Dermatology*. 2016 Sep 1;2(3):85-8.

Copyright © 2021, Bangladesh Society of Aesthetic Plastic Surgeons. This is an open-access article distributed under the terms of the Creative Commons Attribution 4.0 International license.

Received: 08 May. 2021

Accepted: 09 June. 2021

PDF Downloaded use this QR code →

