

Original Article

Diced Cartilage Fascia Technique with a Single Incision for Dorsal Augmentation in Rhinoplasty

Choudhury I¹, Siddiky SA²

Abstract

This paper aimed at a newer technique for dorsal augmentation during rhinoplasty using diced cartilage wrapped in fascia. The usage of diced cartilage has been variously described in the literature with consistently satisfactory results. We present our early experience with patients undergoing dorsal augmentation during rhinoplasty using an updated method of diced cartilage wrapped in fascia with a single incision at donor site. The term is broadly descriptive and there remains a wide-range of ways to execute. Updating and enhancing the technique with greater attention to create precision, and creating an aesthetically optimal and predictable result, may improve outcomes for future patients.

Keywords: Rhinoplasty, revision rhinoplasty, dorsal augmentation, costal cartilage, diced cartilage, DCF, diced cartilage fascia.

Introduction

The history of dorsal augmentation during rhinoplasty emulates in many ways the progression of increasingly higher standards of care in medicine, driven by technological advances and rapidly evolving therapies. Early attempts were decidedly crude, with a wide assortment of everyday materials including ivory¹ and jade used to increase the height of the nose. Though the years, surgeons have attempted to improve outcomes by utilizing a variety of autologous and alloplastic materials, including cartilage, bone²⁻⁴, fascia, diced cartilage silicone, polytetrafluoroethylene, and various type of incisions have also been used. All with mixed results⁵.

When many contemporary surgeons favor autologous grafts in an onlay configuration for mild to moderate amounts of dorsal augmentations^{2,6,10} on demand a larger volume of graft materials have prompted surgeons to explore alloplastic (silicone, Goretex, etc.)

and homoplastic (irradiated costal cartilage) options. The use of Artificial implants can obviate the need for donor site incision and its morbidity²⁻⁵.

However, a primary downside of artificial implants can be a relatively high risk of complications compared to autologous graft techniques, driving some surgeons to pursue this avenue.

The use of diced cartilage in dorsal augmentation has been periodically documented in the English literature as early as 1943 by Peer, in 1951 by Cottle, and in 1968 by Burian, though it did not gain wide-spread acceptance at the time.⁶⁻⁷ Guerrerosantos revisited this concept in the 1990s⁸, refining the technique by wrapping fragmented cartilage in fascia, while Erol brought a larger audience with his description of wrapping diced cartilage in Surgicel in 2000⁹. Daniel subsequently brought a renewed interested in wrapping diced cartilage in fascia^{6,7}. Modifications of the concept of using diced cartilage as the building block for dorsal augmentation have been variously described, primarily adding assorted tissue adhesives to ease shaping of the graft, altering the material wrapping the cartilage or foregoing an encasement altogether^{9,10,11}. The manifold existing descriptions in the literature notwithstanding, a systematic approach refining the surgical technique to achieve greater precision and consistency using diced cartilage with fascia has not been previously delineated.

Diced cartilage with facial harvest in a same incision represents a potentially ideal graft for dorsal

1. Imran Choudhury, Asso Prof. Enam Medical College Hospital, Savar, Dhaka.
2. Sayeed Ahmed Siddiky, FCPS, FRCS, FACS, Consultant Plastic & Aesthetic Surgeon Cosmetic Surgery Centre Ltd & Bangladesh Specialized Hospital Ltd. Dhaka, Bangladesh

Correspondence to:

Prof. Sayeed Ahmed Siddiky, FCPS, FRCS, FACS,
Consult-ant Plastic & Aesthetic Surgeon Cosmetic Surgery
Centre Ltd & Bangladesh Specialized Hospital Ltd. Dhaka,
Bangla-desh. Email: sasiddiky@gmail.com
Mob: +880 1911 352 546

augmentation, as it makes use of the lower complication rates associated with autologous grafts, while also providing a graft that has the ability to recreate dorsal aesthetic lines in a natural and predictable manner. The usage of diced cartilage has been variously described in the literature, with consistently satisfactory result. Herein, we present our early experience, with patients undergoing dorsal augmentation during rhinoplasty using an updated method of diced cartilage wrapped in fascia using a single incision at donor site.

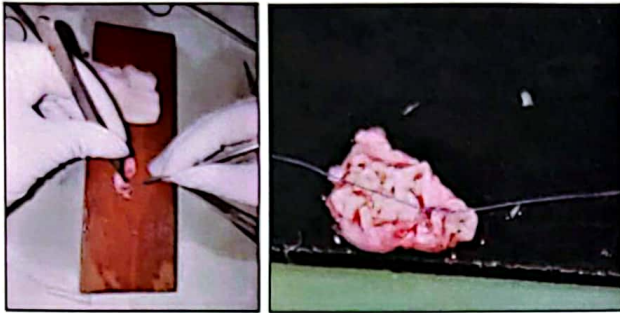


Figure 1: Conchal cartilage sliced into microdices.

Figure 2: Microdiced cartilage being wrapped in retroauricular fascia.

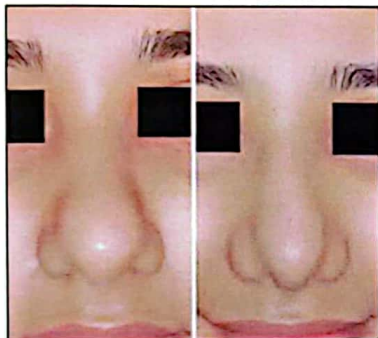

Figure 3: Before and after Microdiced Cartilage Fascia Augmentation Rhinoplasty - front view.

Materials & Methods

Total of 3 patient were operated for nasal dorsal augmentation, during a period of 4 months from October 2019 to January 2020. All 3 patients were female; age range was 22 to 31 years.

Procedure

After proper assessment and under general anesthesia, conchal cartilage was harvested from the auricle using vertical incision posteriorly. After harvesting, the end of the incision was extended upward and backward into the scalp in a zigzag manner. Retroauricular fascia was then harvested. The length and width of the

harvested fascia depended on the dimension of the cartilage graft. Hemostasis was ensured with diathermy. Closure was attained by 4/0 vicryl. By open rhinoplasty method dorsal tunnel was dissected along the midline. Lower alar cartilages (LAC) were trimmed and fibrofatty tissue debulking from the tip was done as required. The Conchal cartilage was sliced into microdices using a sharp blade. (Figure 1) The retroauricular fascia was spreadout onto a wooden board and pinned at four comers. The microdiced cartilage was aligned vertically and the fascia wrapped around it. (Figure 2) The facial margins were than sutured by 4/0 vicryl. This diced cartilage fascia graft was then gently inserted in the dorsal tunnel. Necessary moulding was done to attain the desired shape. The LACs were apposed in the midline again using 4/0 vicryl. Would closure was done with 6/0 prolene and 4/0 vicryl. Light nasal pack and malleable external splint was applied.

Results

The results of all 3 patients were satisfactory and no complications were encountered. Since the follow-up period was small, further flow up is required for assessment of long-term results. (Figure 3)

Discussion

Given the contemporary focus of minimizing complications and creating a sustainable result, many rhinoplasty surgeons have moved towards exclusively using autologous grafts during dorsal augmentation. Diced cartilage fascia techniques have proven fascinating due to its relative pliability, wide availability of materials needed for the construct, and the perceived forgiving nature with regards to contour irregularities¹²

Diced cartilage fascia techniques for dorsal augmentation in rhinoplasty and revision rhinoplasty have been variously utilized and described for over half a century. Although producing satisfactory result in many cases, at the same time has received criticism for creating a "sausage-like" appearance or an otherwise unnatural look to the dorsum. The term is broadly descriptive and there remains a wide-range of ways to execute it^{13,14,15}.

Contour irregularities as well as multiple incisions made for harvesting tissue remain the most common reason for surgeon and patient dissatisfaction after dorsal augmentation using diced cartilage with fascia. Sub-optimal contours may manifest in the form of convexities and concavities, over or under augmentation, deviation, asymmetries,

and unnatural dorsal anesthetic lines^{16,17,30}. Conservative management of minor contour irregularities with nasal scar (especially within the first month following surgery), and directed injections of kenalog and 5-fluorouracil for scar management will successfully address many of the irregularities observed in the early post-operative period^{18,19,20}. Persistent contour irregularities beyond post-operative edema due to coalesced diced cartilage will infrequently warrant revision surgery.

Conclusion

This updated diced cartilage fascia technique with a single incision eliminates an additional donor site incisions and morbidity. It can enhance precision to create more predictable and consistently beautiful results^{23,24}. A further attention on precision approach for practicing the DCF graft may result in even improved outcomes for future patients^{25,26,27}.

References

- Deneck HJ, Meyer R. Plastic Surgery of the Head and Neck. New York: Springer-Verlag; 1967. p. 148.
- Burian F. The Plastic Surgery Atlas. New York: Macmillan; 1968.
- Daniel RK, Calvert JW. Diced cartilage in rhinoplasty surgery. *Plast Reconstr Surg* 2004;113:2156-2171.
- Guerrerosantos J. Rhinoplasty: the "Taco" graft. *Plast Reconstr Surg* 2006. In press.
- Wilflingseder P. Cranioplasties by means of diced cartilage and split rib grafts. *Minerva Chir* 1983;38:837-843.
- Velidedeoglu H, Demir Z, Sahin U, Kurtay A, Ero! 00. Block and Surgicel-wrapped diced solvent-preserved costal cartilage homograft application for nasal augmentation. *Plast Reconstr Surg* 2005;115:2081-93; discussion 2094-7 [Daniel RK].
- Erol 00. The Turkish Delight: a pliable graft for rhinoplasty. *Plast Reconstr Surg* 2000;105:2229-2241.
- Daniel RK. Rhinoplasty-An Atlas of Surgical Techniques. New York: Springer; 2002.
- Calvert JW, et al. Diced cartilage grafts: a histological analysis. *Plast Reconstr Surg* 2006. In press.. Vilar-Sancho B. An old story: an ivory nasal implant. *Aesthetic Plast Surg* 1987;11:157-61.
- Krause CJ. Augmentation rhinoplasty. *Otolaryngol Clin North Am* 1975;8:743-52.
- Wheeler ES, Kawamoto HK, Zarem HA. Bone grafts for nasal reconstruction. *Plast Reconstr Surg* 1982;69:9-18.
- Romo T 3rd, Jablonski RD. Nasal reconstruction using split calvarial grafts. *Otolaryngol Head Neck Surg* 1992;107:622-30. DOI:PubMed
- Leaf N. SMAS autografts for the nasal dorsum. *Plast Reconstr Surg* 1996;97:1249-52. DOI:PubMed
- Daniel RK. Rhinoplasty: an atlas of surgical techniques. New York: Springer; 2002. pp. 11-2.
- Daniel RK, Calvert JW. Diced cartilage grafts in rhinoplasty surgery. *Plast Reconstr Surg* 2004;113:2156-71. PubMed
- Guerrerosantos J, Trabanino C, Guerrerosantos F. Multifragmented cartilage wrapped with fascia in augmentation rhinoplasty. *Plast Reconstr Surg* 2006;117:804-12; discussion 13-6.
- Cerkes N, Basaran K. Diced cartilage grafts wrapped in rectus abdominis fascia for nasal dorsum augmentation. *Plast Reconstr Surg* 2016;137:43-51. DOI:PubMed
- Regnault P. Nasal augmentation in the problem nose. *Aesthetic Plast Surg* 1987;11:1-5. DOI
- Khoo BC. Augmentation rhinoplasty in the orientals. *Plast Reconstr Surg* 1964;34:81-8. PubMed
- Beekhuis GJ. Silastic alar-columellar prosthesis in conjunction with rhinoplasty. *Arch Otolaryngol* 1982;108:429-32. DOI:PubMed
- Wellisz T. Clinical experience with the Medpor porous polyethylene implant. *Aesthetic Plast Surg* 1993;17:339-44. DOI:PubMed
- Godin MS, Waldman SR, Johnson CM Jr. The use of expanded polytetrafluoroethylene (Gore-Tex) in rhinoplasty. A 6-year experience. *Arch Otolaryngol Head Neck Surg* 1995;121:1131-6. DOI:PubMed
- Queen TA, Palmer FR 3rd. Gore-tex for nasal augmentation: a recent series and a review of the literature. *Ann Otol Rhinol Laryngol* 1995;104:850-2. DOI:PubMed
- Adams JS. Grafts and implants in nasal and chin augmentation. A rational approach to material selection. *Otolaryngol Clin North Am* 1987;20:913-30. PubMed
- Juraha LZ. Experience with alternative material for nasal augmentation. *Aesthetic Plast Surg* 1992;16:133-40. DOI
- Gilmore J. Use of vicryl mesh in prevention of post-rhinoplasty dorsal irregularities. *Ann Plast Surg* 1989;22:105-7. DOI:PubMed
- Fanous N. Mersilene tip implants in rhinoplasty: a review of 98 cases. *Plast Reconstr Surg* 1991;87:662-71. discussion 72-3 PubMed
- Gunter JP, Rohrich RJ. Augmentation rhinoplasty: dorsal onlay grafting using shaped autogenous septal cartilage. *Plast Reconstr Surg* 1990;86:39-45. DOI:PubMed
- Peer LA. Diced cartilage grafts: new method for repair of skull defects, mastoid fistula and other deformities. *Arch Otolaryngol* 1943;38:156-65. DOI
- Cottle MH. Nasal surgery in children. *Eye Ear Nose Throat Mon* 1951;30:32-8.

Copyright © 2020, Bangladesh Society of Aesthetic Plastic Surgeons. This is an open-access article distributed under the terms of the Creative Commons Attribution 4.0 International license.

Received: 15 Sept. 2019

Accepted: 15 Nov. 2019

PDF Downloaded use this QR code→

