

Augmentation Mammoplasty using Silicone Implants: First case in Bangladesh

S.A. Siddiky

Abstract

In 1963 Cronin & Gerow first introduced silicone breast implants for augmentation mammoplasty. Numerous scientific studies throughout the world have proved that silicone implants do not cause breast cancer. Even then it took almost 40 years before the first case could be done in our country. Ignorance, false belief, and lack of trained doctors are the reasons behind it.

A 23-year-old lady presented with severely hypoplastic breasts. She was suffering from psychological trauma and social isolation due to her physical deficit. After detailed discussion and counseling, augmentation mammoplasty was done. Under GA, small inframammary incisions were made and submuscular pockets dissected. Silicone implants were then inserted and wound closure attained in two layers.

It was pleasing to see the smile of satisfaction on her face when she saw and touched her newly constructed breasts. Within 24 hours the patient went home and after 6 months of the surgery, she is free from mental agony and has no complains. Complications like bleeding, hematoma, infection, implant displacement or capsular contracture can occur but none of them were encountered in this patient.

The author believes that a short hands on training program with particular attention to counseling and dissection, augmentation mammoplasty may be a regular operation for the plastic surgeons of Bangladesh.

Key words

Augmentation mammoplasty, Silicone implants

Introduction

There has been various misinformation and skepticism in the general public and in many of our doctors regarding the safety in the use of silicone breast implants. Numerous scientific studies carried out in the USA and UK has failed to establish any link between breast cancer and silicone implants^{1,2}. Further studies have also proved that silicone implants do not cause cancer elsewhere in the body. It also has no known link with collagen disease.

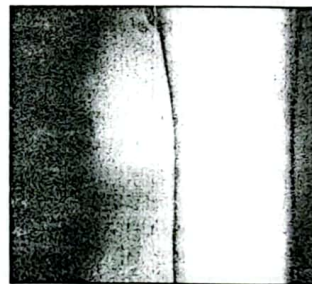
At present augmentation mammoplasty is an established plastic surgical procedure in the western world. More than 200,000 women have undergone this surgery last year in the USA alone. Even in neighboring India it is a commonly performed operation. Unfortunately we have lagged far behind in this field- the reasons being lack of insight, ignorance and absence of trained surgeons interested in this field.

In September 2000 the first case of augmentation mammoplasty was done successfully by the author at Japan Bangladesh Friendship Hospital, Dhaka. The ease with which this surgery could relieve the pain of


psychological trauma in a young lady prompted this case report.

Case Report

A young lady of 23 years presented with the complain of poor development of her breasts. She was married and had a three-year-old child. After puberty she noticed that her breasts were not developing properly. As years went by it became a growing concern for her. Due to her flat-chested appearance she suffered constantly from the pain of psychological trauma. She frequently faced embarrassment in parties and family get togethers. Even the use of padded brassiere could not save her from occasional humiliation by friends and relative. This gradually led her to social isolation.



Preoperative picture of a young lady with severely hypoplastic breast



The same lady after augmentation mammoplasty

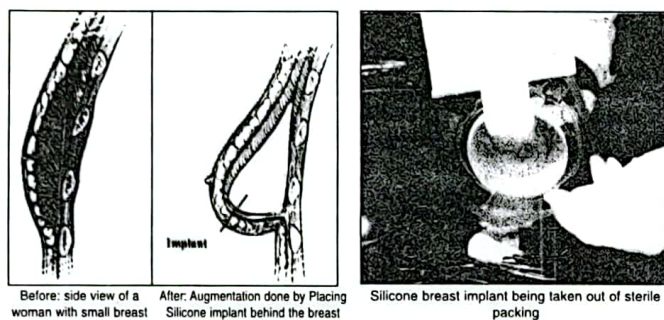
She struggled to retain a normal marital relationship and thanked to her extremely cooperative and understanding husband. "I don't feel like a woman; it seems that I am cheating on my husband"- she wept. During the last few years she went to a number of specialists in Dhaka but none could help her. On examination her breasts were found to be grossly hypoplastic. The nipple-areola complex was normal but there was a distinct absence of the breast mound. This made her look rather flat chested. Measurements revealed a 31" chest circumference with a cup size of A(-). Routine investigations were done and all of them came out normal. Detailed discussion about augmentation mammoplasty was done. Multiple consultations were made with the patient and her husband before a final date for operation was given. The consultations were deliberately spread over a period of two months, so that the details of the surgical procedure and possible complications could be discussed. This allowed the patient and her husband to go through different reference papers and the latest Internet information.

Procedure

Before operation the patient was asked to take soap water bath daily for five days (including the morning of surgery). The inframammary folds and the proposed lines of incision were marked out with the patient in sitting position. Under general anesthesia, submuscular pockets were dissected behind the pectoralis major muscle. Small

1. Dr. S.A. Siddiky, FRCS, FCPS, FICS, FACS, Consultant Plastic Surgeon, Pioneer Dental College and Hospital, Japan Bangladesh Friendship Hospital, Dhaka.

incisions (2.5") near the submammary folds were utilized for access. After absolute hemostasis, 150 ml round, moderate profile, silicone implants were inserted into the pockets. Careful movement of the index fingers helped the 10.5 cm diameter implants to be inserted through an incision almost half its size. After assessing the implant position and external symmetry, closure of the incisions were done in two layers. The deeper layer took care of the inframammary fold- preventing subsequent downward displacement of the implant; and the skin was closed by a continuous subcuticular 6/0 vicryl. Special care was taken to avoid pricking the implant during placement of the sutures. Drains were not employed, and the use of local steroid avoided.



Postoperative recovery was rapid. It was very pleasing to see the smile of satisfaction on her face as she saw and touched her newly constructed breasts. The patient went home after 20 hours of the operation. Complications like bleeding, hematoma, infection, implant displacement, or disruption were not encountered. Nipple sensation was intact. The patient comes for regular follow-up and after six months of surgery there is no evidence of capsular contracture, as evidenced by an entirely normal soft consistency of the breasts. She has been advised to come back for regular follow-up. Free from her social isolation and mental agony, the patient is now a happy woman leading an entirely normal life.

Discussion

It is imperative that plastic surgeons and related health personnel in our country should address the social and psychological problems related with abnormal breast development in women. Women with hypoplastic breasts suffer immensely from their incomplete and disproportionate figure. Since the pain is deep down and silent it may be hard to recognize until one talk to them in confidence. Patients who had their breast removed for cancer should also be considered in the same sympathetic manner. Hundreds of mastectomies are being done throughout the country, many of them can in fact benefit from breast reconstruction. Suitable patients with early breast cancer should therefore be considered for reconstructive mammoplasty. Immediate reconstruction with muscle flaps and/or silicone implants can be done in selected cases¹. This can alleviate the psychological trauma of disfigurement resulting from breast removal.

One should not think that augmentation mammoplasty is an abuse of plastic surgery meant to increase indecency in our society; rather it is a gift of science which can help restore normalcy in many unlucky women.

For hundreds of years men have tried to augment the breast by implanting different materials such as ivory,

wool, sponge, and fat transplanted from other parts of the body⁴. Because of various complications none of them could stand the test of time. Silicone breast implant was first introduced by Cronin & Gerow in 1963. Since then it has been accepted as the only reliable material for use in augmentation mammoplasty⁴. Liposuction, which is a popular cosmetic surgery in the west, took 30 years before it could be started in Bangladesh⁵. Augmentation mammoplasty took almost 40 years before the first case was done in our country.

In 1991 a batch of silicone implants which had an outer coating of polyurethane was removed from the US market. It was done after a research finding revealed that polyurethane breakdown product is carcinogenic in rats⁶. Nowadays polyurethane is no longer used in the manufacture of silicone breast implants; and till date these silicone implants have been found not to cause cancer in humans or in rats. In fact studies in Canada and USA has shown a lower incidence of breast cancer in patients with long term exposure to silicone implants¹².

There are four different approaches that can be used for insertion of breast implants: they are inframammary, periareolar, axillary, and umbilical. The pocket dissected for implant placement can either be subglandular (in between the breast and the pectoralis major muscle) or submuscular (behind the pectoralis major muscle). In this patient the implants were placed in the submuscular plane because the glandular element was very thin.

It is important to discuss in detail the procedure and the possible complications with the patient. Capsular contracture can be minimized by careful dissection, adequate pocket size, absolute hemostasis, accurate selection of implant size, and by instituting regular self message early in the postoperative period⁴. There are numerous companies producing breast implants, but the surgeon should use the brand, which he is familiar with. It is not wise to use implants coming from unknown companies. In reduction mammoplasty, lactation and nipple sensation can become hampered. But in augmentation mammoplasty pregnancy and breast-feeding is not hampered. Nipple sensation also remains unaltered.

Conclusion

Numerous scientific studies have proved that silicone breast implants do not cause cancer. Augmentation mammoplasty is a gift of science which can help alleviate the pain of psychological trauma in women with hypoplastic breasts and in those who had their breast removed for cancer.

References

1. Berkel H, Birdsall DC, and Jenkins M. Breast augmentation: a risk factor for breast cancer? *N. Engl. J. Med.* 326:1649, 1992.
2. Brody G. Silicone implants and the inhibition of cancer. *Plast. Reconstr. Surg.* 96:519, 1995.
3. Grotting JC, Urist M, Maddox WA, et al. Conventional TRAM flap versus microsurgical TRAM flap for immediate breast reconstruction. *Plast. Reconstr. Surg.* 83:828, 1989.
4. Coburn RJ, dehaan CR and Fisher JB. Augmentation mammoplasty. In Stark RB. and Aufricht C. Editors. *Aesthetic Plastic Surgery*. New York: Little, Brown and company, 381-408 (1980).
5. Siddiky SA, Rahman A, et al. Tulip Liposuction: A New Technique in Bangladesh. *Journal of Dhaka Medical College.* 1999 Oct:120-25.
6. Fisher JC. The silicone controversy: When will science prevail? *N. Engl. J. Med.* 326:1696, 1992.