

Original Article

Procedure, Applications and Outcomes of Lipoinjection for Soft Tissue Augmentation

Islam MT¹, Siddiky SA²

Abstract

Introduction: Plastic surgeons all over the world are challenged with a dramatically increased public interest and demand for aesthetic contouring surgery. There is growing advocacy for autologous fat transfer techniques for contouring various defects among surgeons due to its safety, flexibility and long-lasting results.

Methods: This study was conducted between March 2017 to July 2019. Patients with contour deformities were enrolled consecutively. All participants were subjected to a full clinical history and general clinical examination with laboratory findings to confirm their fitness for surgery. Fat harvested and lipoinjection procedure performed. Patients were followed up for six months and beyond. Surgeon satisfaction and patient satisfaction assessment was performed by clinical examination and comparing the preoperative and six-month postoperative photographs.

Results: Total 22 patients were included in the study of which 19 patients were female and 3 patients male. Indications of lipoinjection were-Facial rejuvenation¹, Hand rejuvenation⁴, Breast augmentation and asymmetry³, Facial Scar¹, Gluteal augmentation³. Overall results of the procedure were excellent.

Conclusion: Soft tissue augmentation with autologous fat, which leaves no incisional scar and lacks the complications associated with foreign materials, can be an ideal procedure for plastic surgeons.

Keywords: Lipoinjection, Operative technique, Applications.

Introduction

Autologous fat grafting is a frequently employed procedure in cosmetic and reconstructive surgery. Fat is a versatile filler for treating contour irregularities of different parts of body due to congenital disorders, acquired diseases, and traumatic and ageing deformities. Unlike many other fillers of synthetic origin, fat is easy to procure with minimal donor site morbidity.

Additionally, it is frequently available as autologous and thus without immunogenicity issues. Moreover, its soft and dynamic nature makes it useful especially for cosmetic and reconstructive surgery¹.

1. Mirza Mohammad Tyeabul Islam, Assistant professor and Head, Department of Plastic Surgery, Cumilla Medical College, Cumilla.
2. Sayeed Ahmed Siddiky, FCPS, FRCS, FACS Consultant Plastic & Aesthetic Surgeon, Cosmetic Surgery Centre Ltd, Dhanmondi, Dhaka.

Correspondence to:

Mirza Mohammad Tyeabul Islam, Assistant Professor and Head, Department of Plastic Surgery, Cumilla Medical College, Cumilla
Email: tyemirza@hotmail.com Mob: 01717435212

The fat tissue collected by suction contains not only adipocytes, but also a significant number of cellular elements from the stromal vascular fraction, such as endothelial cells, pericytes, fibroblasts, and Adipose-derived stem cells (ASCs). ASCs and other cells with regenerative characteristics present in the aspirated fatty tissue play an important role in the viability of these grafts². Studies have shown that one of the main advantages of ASCs is the production of growth factors, which have angiogenic and anti-apoptotic properties that lead to increased graft survival³. These growth factors increase the capillary density and improve the quality of the graft, thereby contributing to better long-term survival⁴.

Historically, the use of fat grafts to correct congenital deformities and complex traumatic wounds with soft-tissue loss after radical oncological surgery was proposed in 1893 by Neuber, by Hollander in 1912, by Neuhof in 1921, and by Josef in 1931⁵. The liposuction technique, introduced by Fisher in 1974, followed by the tumescent technique, introduced by Klein in 1985, accelerated the development of the lipofilling technique. Since the 1980s, autologous fat

transplantation has been one of the most popular procedures performed by plastic surgeons⁶.

Methods

This is a prospective observational study conducted in authors' private work place. 22 patients with contour deformities were enrolled consecutively from March 2017 to July 2019. Demographic and clinical data of patients was collected after obtaining informed written consent. All participants were subjected to a full clinical history and general clinical examination with laboratory findings to confirm their fitness for surgery. The exclusion criteria included patients with the following conditions: coagulopathies, uncontrolled hypertension, obligatory antiplatelet and anticoagulant drug administration, unrealistic expectations, high BMI (35 or greater), significant weight loss, musculoskeletal anomalies and poor compliance to the follow-up program.

Photographic documentation was acquired preoperatively and at the end of the one month, 3 months and six post-operative months. The photography session during the last follow-up visit was considered to be the post-operative photographic result as long as it was taken six months or more after surgery.

Operative technique

Fat Harvest and Processing:

Depending on patient desire and accessibility, fat was harvested from either the abdomen or the medial side of the thigh. Under local or general anesthesia, Fat was harvested using a 3mm, two-hole, blunt cannula attached to a 20 ml Luer-Loe syringe. The plunger of a 20 cc syringe was pulled back only a few milliliters during suctioning to evade unnecessary negative pressure and to avoid fat cell rupturing. The required amount to fill the contour deformity was harvested accordingly on the basis of clinical judgment.

Lipoinjection:

After activation, fat was injected through a 1.5mm blunt-tip cannula, with a lateral opening using small stab incisions. Fat was placed gently during the withdrawal of the cannula. Fat was placed in small fractions at different depths of soft tissue. End point of lipoinjection was achieved by visual clinical impression.

Patients were given intravenous third-generation cephalosporin during the procedure and discharged on oral antibiotic for a week. The patients were followed up at monthly intervals for six months. All the patients were observed for possible complications such as

infection, bruising, swelling, skin necrosis, hematoma, seroma, and uneven skin texture.

Surgeon satisfaction and patient satisfaction assessment was performed by clinical and overall appearance. It was done by clinical examination and comparing the preoperative and six-month postoperative photographs.

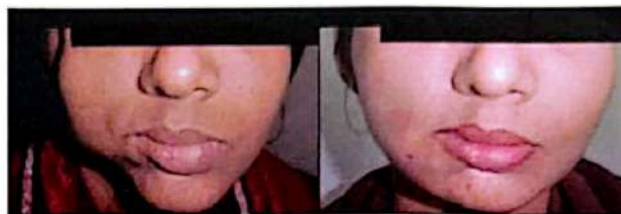

Figure 1: Before & after lipoinjection for a patient with Parry Romb syndrome

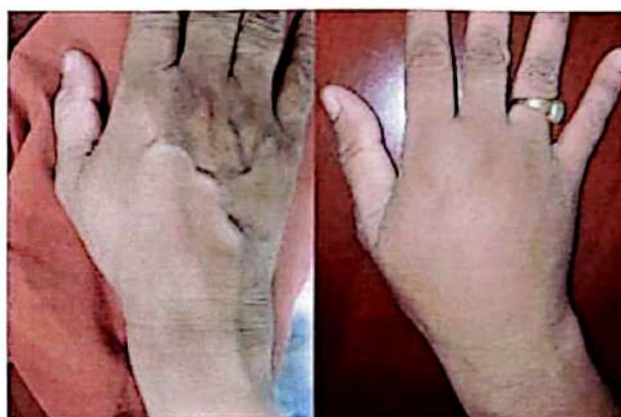

Figure 2: Before & after lipoinjection for hand rejuvenation

Results

Total 22 patients participated in the study.

Table 1

Patient characteristics	(n=22)
Males	3
Females	19

Table 2

Indication of lipoinjection

Indication	No. of pt.
Facial rejuvenation/hemifacial atrophy	11
Hand rejuvenation	4
Gluteal augmentation	3
Breast augmentation and asymmetry	3
Scar	1

Table 3

Complication of the lipoinjection Procedure	
Seroma formation	1
Infection	1

Table 4

Patient satisfaction data	
Excellent	16
Fair	6

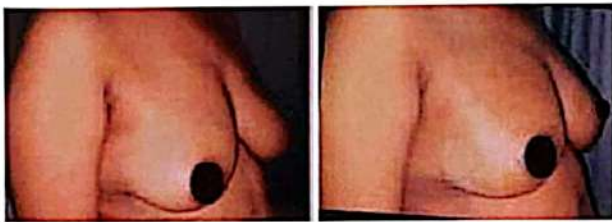


Figure 3: Before & after lipoinjection for breast augmentation

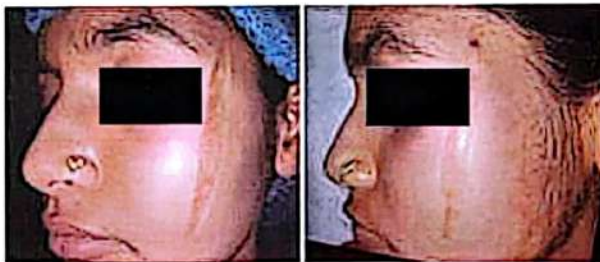


Figure 4: Before & after lipoinjection for depressed scar

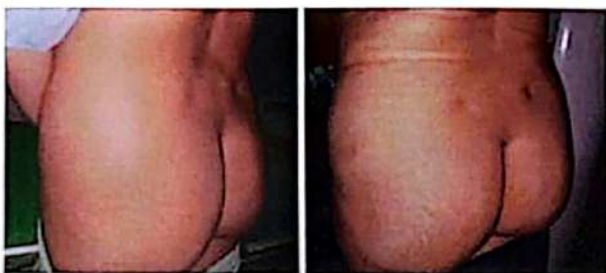

Figure 5: before & after lipoinjection for hip augmentation

Discussion

In the present study, clinical outcomes of treatment of contour deformities with lipoinjection was observed. Patient and physician satisfaction has a pivotal role especially in facial plastic surgery. Fat injection has been used for more than 20 years as a relatively low-

risk and low-morbidity procedure to correct a variety of soft tissue defects in the face, trunk, and extremities. Fat grafts are easily available, biocompatible, associated with low donor-site morbidity, and provide a natural appearance.

Fat transplantation techniques have dramatically changed over the last two decades, from dermal fat grafting where chunks of fat was transferred, which had limited success in the consistent replacement of volume defects, to lipoinjection of aspirated fat after liposuction. This latter procedure, if properly executed, could have a high regenerative potential for both simple volume replacement as well as Aesthetic enhancement of overlying skin. ASCs are similar to bone marrow-derived stem cells in that they are capable of differentiating into multiple mesodermal tissue types and show similar surface protein marker expression⁷. ASCs are different from bone marrow-derived mesenchymal stem cells because they can be easily obtained using a standard wet liposuction procedure under local anesthesia. ASCs are part of the stromal vascular fraction (SVF) of adipose tissue and secrete vascular endothelial growth factor, hepatocyte growth factor, and transforming growth factor-B in the presence of stimuli such as hypoxia and other growth factors and strongly influence the differentiation of stem cells, promoting angiogenesis and wound healing, and potentially aiding new tissue growth and development⁸.

Applications

1. Facial rejuvenation:

Autologous fat grafting has an important role in facial rejuvenation. In fact, the unique regenerative potential of lipoinjection leads to excellent results due to its filling properties and the role of ASCs. The loss of facial volume, especially in the periorbital region, is an important component of aging and is due to the redistribution and atrophy of facial fat. Aesthetically, the main surgical indications of lipoinjection for facial rejuvenation are the correction of dark circles, as an adjuvant to blepharoplasty, or as an alternative treatment for hollow eyes and malar bags. Lipoinjection is also a very efficient procedure for correction of hemifacial atrophy in Parry Romberg syndrome.

Complications like infection and skin necrosis due to vascular occlusion can occur. But the most dangerous complication of lipoinjection in the face is permanent blindness. This occurs due to inadvertent intravascular injection of fat occluding the central artery of retina.

2. Hand rejuvenation:

The appearance of the hands is a tell-tale sign of a person's true age. Aging also leads to intrinsic effects such as the gradual disappearance of subcutaneous fullness and tissue atrophy due to collagen depletion and dehydration. This leads to dorsal skin wrinkling and greater visibility of the extensor tendons, and makes subcutaneous veins appear more blue and tortuous.

Because fat not only serves as a filler but also has the regenerative potential to improve the quality of soft tissue and skin on the dorsal side of the hands, fat grafting is an attractive procedure for hand rejuvenation. Under local anesthesia, the fat graft is injected using blunt cannulas to reduce the risk of dorsal vein perforation. Between 10 and 30 mL of fat should be injected to give the hand a puffy, slightly overfilled look. A small volume of fat tissue should also be injected at the base of each finger, to give a uniform appearance to the whole hand⁹.

3. Breast augmentation/reconstruction:

Autologous fat transplantation is widely used in aesthetic breast augmentation as well as in reconstructive breast surgery. The advantage of breast augmentation by lipoinjection is that there is no surgical scars after the procedure, in contrast augmentation done with silicone implants. An artificial material can also be avoided in this procedure. But the disadvantage is that the patient requires two or more sessions to achieve the desired augmentation. This is because 40% or so of the injected fat is reabsorbed after each session. Lipoinjection can also be a simple solution in reconstructive mammoplasty. Lipoinjection can be used to correct contour defects in the immediate or late postoperative period, secondary contour defects.

4. Scars:

Fat transplantation can be used not only to fill atrophic scars but also to reduce scar contracture as a regenerative alternative to other surgical techniques. This is made possible by the presence of ASCs in the fat tissue. The skin and subcutaneous can be destroyed in cases of thermal injury or after trauma. Autologous fat grafts show the ability to regenerate the dermis and subcutaneous tissue and improve the dermal quality in scar areas.

5. Gluteal augmentation:

Gluteal augmentation is often performed by means of intramuscular implants, but lipoinjection of hip commonly referred to as Brazilian Butt lift (BBL) has gained popularity in recent times. Fat grafting plays an important role in gluteal augmentation and may replace implant-based gluteal augmentation in some cases, if the patient has great enough amount of fat as a donor site¹⁰. Now a days hybrid procedure is becoming popular where lipoinjection is combined with silicone implant.

Every step in fat transplantation, i.e., harvesting, processing, and transplantation, is important, but viability of the harvested fat cells is crucial. The chances of survival are higher if graft manipulation is less and if it is quickly reinjected.

Donor-site complications appear to be minimal and related to the liposuction technique. The possible complications include bruising, swelling, haematoma formation, paraesthesia or donor-site pain, infection, contour irregularities, and damage to the underlying structures for example due to the intraperitoneal or intramuscular penetration of the cannula¹¹. But the most dreadful complication of Brazilian butt lift is venous fat embolism leading to death. This happens due to inadvertent injury to the Inferior Gluteal veins and subsequent fat embolism in the lungs. After some recent mishaps this has been proved in autopsies. As a result new guideline and restriction has been issued by ASAPS and ISAPS¹².

In the current study, one patient had seroma formation requiring aspiration, and another patient had infection at the injection side that responded to oral antibiotic therapy. There was no features of fat embolism in any patient.

Conclusion

Soft tissue augmentation with autologous fat, which leaves no scar and lacks the complications associated with foreign materials, can be an ideal procedure in aesthetic as well as in reconstructive plastic surgery. Lipoinjection can be used for various indications, not only for its filler effects but also for its regenerative potentials.

References

1. P. Pasquale, M. Gaetano, D. A. O. Giovanni, C. Luigi, and S. Gilberto, "Autologous fat grafting in facial volumetric restoration," *The Journal of Craniofacial Surgery*, vol.26, no. 3, pp. 756-759,2015.
2. Rigotti G, Marchi A, Sbarbati A. Adipose-derived mesenchymal stem cells: past, present, and future. *Aesthetic PlastSurg* 2009;33:271-3.
3. Yoshimura K, Sato K, Aoi N, et al. Cell-assisted lipotransfer for facial lipoatrophy: efficacy of clinical use of adipose-derived stem cells. *DermatolSurg* 2008;34:1178-85.
4. Zhu M, Zhou Z, Chen Y, et al. Supplementation of fat grafts with adipose-derived regenerative cells improves long-term graft retention. *Ann Plast Surg* 2010;64:222-8.
5. E. Billings Jr., J.W. May Jr., Historical review and present status of free fat graft autotransplantation in plastic and reconstructive surgery, *Plast. Reconstr. Surg.* 83 (1989) 368-381.
6. B.W. Li, W.C. Liao, S.H. Wu, H. Ma, Cryopreservation of fat tissue and application in autologous fat graft: in vitro and in vivo study, *Aesthet. Plast. Surg.* 36 (2012) 714-722.
7. G. Caruana, N. Bertozzi, E. Boschi, M. PioGrieco, E. Grignaffini, E. Raposio, Role of adipose-derived stem cells in chronic cutaneous wound healing, *Ann. Ital. Chir.* 86 (2015) 1-4.
8. A.J. Salgado, R.L. Reis, N.J. Sousa, J.M. Gimble, Adipose tissue-derived stem cells secretome: soluble factors and their roles in regenerative medicine, *Curr. Stem Cell Res. Ther.* 5 (2010) 103-110.
9. D. Hoang, M.I. Orgel, D.A. Kulber, Hand rejuvenation: a comprehensive review of fat grafting, *J. Hand Surg. Am.* 41 (2016) 639-644.
10. L.L. Pu, K. Yoshimura, S.R. Coleman, Future perspectives of fat grafting, *Clin. Plast. Surg.* 42 (2015) 389-394.
11. C.W. Chan, S.J. McCulley, R.D. Macmillan, Autologous fat transfer: a review of the literature with a focus on breast cancer surgery, *J. Plast. Reconstr. Aesthet. Surg.* 61 (2008) 1438-1448.
12. Mofid MM. Teitelbaum S. Suissa D et al Report on nortality from glufeal fat gralting, Recommendation from the ASERE Task ferce Aesthet Sung] 2017. Jul; 37 (7) 796 - 806.

Copyright © 2020, Bangladesh Society of Aesthetic Plastic Surgeons. This is an open-access article distributed under the terms of the Creative Commons Attribution 4.0 International license.

Received: 27 Sept. 2019

Accepted: 25 Nov. 2019

PDF Downloaded use this QR code→

