

Original Article

Drainless Lipoabdominoplasty: My Experience in Bangladesh

Siddiky SA

Abstract

Introduction: The use of drains during lipoabdominoplasty operation has been a routine procedure all along. This is done to prevent seroma formation. But there are problems associated with drains, such as, pain, difficulty in patient mobilization, blockage, and infection¹. Strategies to prevent seroma has been tried². But with improvement in dissection technique along with other strategies to prevent seroma, surgeons have now started to avoid using drains. The aim of this study is to see the incidence of complications especially when drain is not employed.

Materials and Methods: The study was carried out in Cosmetic Surgery Centre Ltd and Bangladesh Specialized Hospital Ltd, Dhaka. Period of study 2y 06 month from June 2017 to December 2019. Number of Lipoabdominoplasties done was 47. Females were 44 and males were 03. All the patients were operated under spinal anesthesia except 3, in whom general anesthesia was applied for additional procedures Fascia Scarpa sparing lipoabdominoplasties were performed in all cases. No drains were used in 46 patients. But in one case, drain had to be employed due to excessive preoperative oozing. Postoperatively patients were evaluated for seroma formation, wound dehiscence, flap necrosis and infection.

Results: Only 4 patients amongst drainless abdominoplasty had seroma formation and one patient in whom drain was used had a minor wound dehiscence. None of the patients had flap necrosis or infection. Early mobilization was easier in patients without drain. **Conclusions:** We found that sparing the infraumbilical fascia Scarpa during dissection along with wound closure without tension and avoidance of gliding surfaces with the use of quilting sutures can help avoid the use of drain in lipoabdominoplasty operation. Avoiding drains permits better patients comfort and early ambulation.

Keywords: Lipoabdominoplasty, Drainless, Deroma.

Introduction

The use of drains during lipoabdominoplasty operation has been a routine procedure all along. This is done to prevent seroma formation. But there are problems associated with drains, such as, pain, difficulty in patient mobilization, blockage, and infection. Strategies to prevent seroma, such as the use of quilting sutures^{3,4} or tissue glues⁵ have all been employed.

But with improvement in dissection technique along with other strategies to prevent seroma, surgeons have now started to avoid using drains. The anatomical basis (Fig 1) of modification of this surgical technique lies in anatomical knowledge of lymphatic drainage of the abdominal wall⁶. After attending the ISAPS congress in Miami in 2018 the author has become more convinced about drainless lipoabdominoplasty. In my centres drain is now used only in cases where it is absolutely indicated. The aim of this study is to see the incidence of complications especially when drain is not employed.

Sayed Ahmed Siddiky, FCPS, FRCS, FACS Consultant
Plastic & Aesthetic Surgeon Institute: Cosmetic Surgery
Centre Ltd & Bangladesh Specialized Hospital Ltd Dhaka,
Bangladesh

Correspondence to:

Prof. Sayeed Ahmed Siddiky, FCPS, FRCS, FACS Consultant
Plastic & Aesthetic Surgeon Institute: Cosmetic Surgery
Centre Ltd & Bangladesh Specialized Hospital Ltd Dhaka,
Bangladesh
Email: sasiddiky@gmail.com
Mob: +880 1911 352 546

Materials and Methods

The study was carried out in Cosmetic Surgery Centre Ltd and Bangladesh Specialized Hospital Ltd, Dhaka.

Period of study 2y 06 month from June 2017 to December 2019.

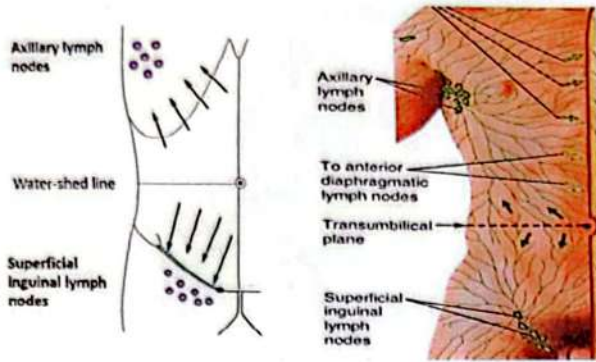


Figure 1: Anatomical basis depend on the lymphatic drainage. Infrumbilical fascia Scarpa carries the lymphatic channels to the inguinal lymph nodes

Number of Lipoabdominoplasties done was 47. Females were 44 and males were 03. All the patients were operated under spinal anesthesia except 3, in whom general anesthesia was applied for additional procedures Fascia Scarpa sparing lipoabdominoplasties were performed in all cases. No drains were used in 46 patients. But in one case, drain had to be employed due to excessive preoperative oozing. Postoperatively patients were evaluated for seroma formation, wound dehiscence, flap necrosis and infection.

Table 1

Total number	47
Females	44
Males	03

Postoperative Care

All abdominoplasty surgeries alone or in combination with other procedures were advised breathing exercise and continued with sequential compression devise for lower limbs.

Typically, the patient ambulates with assistance within 24 hours after completion of surgery.

Routine follow-up is scheduled at 2 days, 6 days, 10 days, 2 weeks, 1 month, 2 months, and 1 year after surgery (Fig 5, 6, 7, 8, 9,10, 11, 12). The abdominal binder / compression garment is placed and worn at all times except during showers for 6 weeks postoperatively.

Methods

Only four patients amongst drainless abdominoplasty had seroma formation and one patient in whom drain was used had a minor wound dehiscence. None of the patients had flap necrosis or infection. Early mobilization was easier in patients without drain.

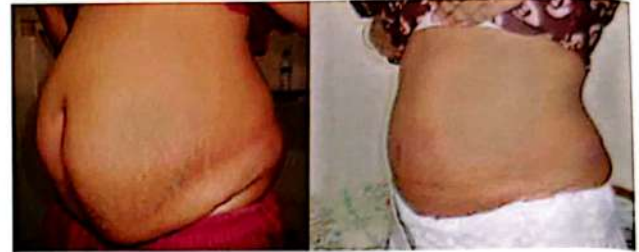

Figure 5: Before and after Lipoabdominoplasty

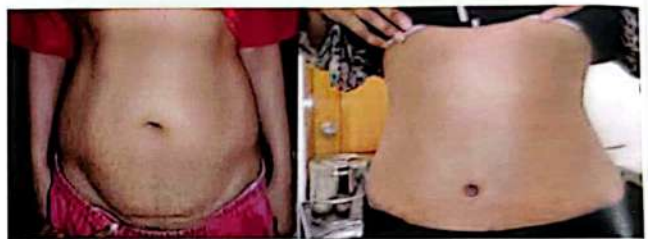

Figure 6: Before and after Lipoabdominoplasty

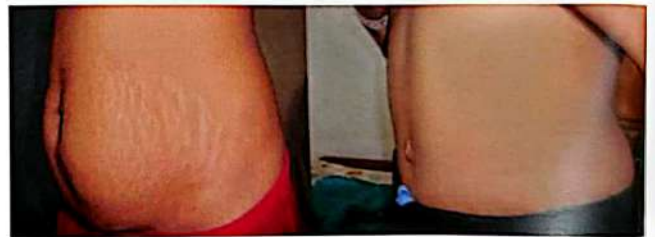

Figure 7: Before and after Lipoabdominoplasty; significant reduction of stretch marks is noted

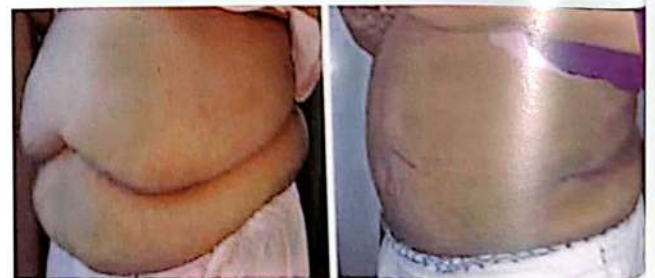

Figure 8: Before and after Lipoabdominoplasty

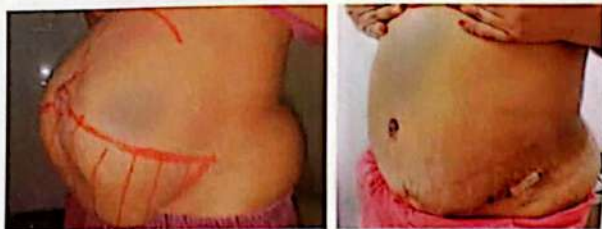

Figure 9: Before and after Lipoabdominoplasty and Ventral Hernia Repair

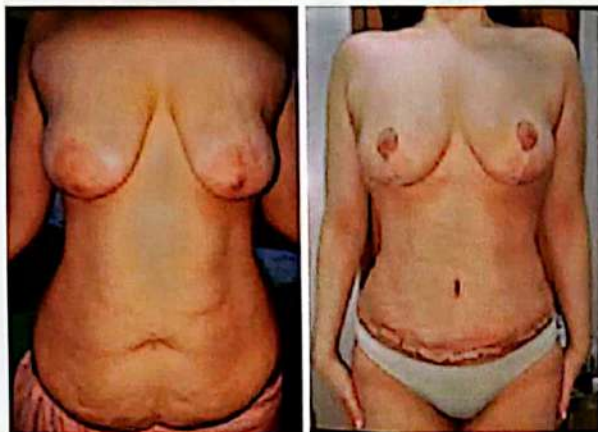


Figure 10: Post massive weight loss laxity of breast and abdomen, in a young lady; before and two weeks after Lipoabdominoplasty and Mastopexy.

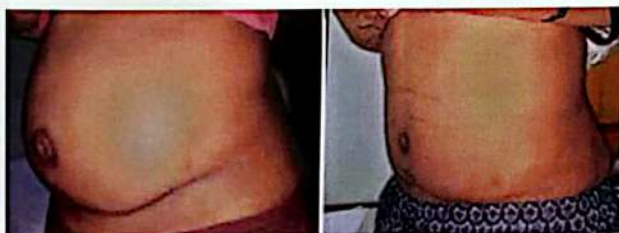

Figure 11: Before and after Revision Lipoabdominoplasty with Umbilical Hernia repair

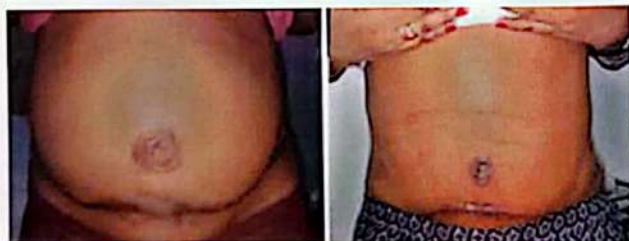

Figure 12: Same patient as in figure 11, front view

Procedure:

In the preoperative room, our warming protocol is started and continued throughout surgery and while in the recovery room. All patients receive lower extremity sequential compression devices⁷.

Table 2

Operative Sequence for Drainless Abdominoplasty	
Step	Details
1	Marking (Fig 2)
2	Infiltration
3	Liposuction
4	Umbilical dissection (Fig 3)
5	Infraumbilical dissection with sub-Scarpal fat preservation
6	Supraumbilical dissection (Fig 4)
7	Excision of sub-Scarpal fat where diastasis recti repair will be performed (if indicated)
8	Vertical midline plication using No 1 prolene
9	Marking and excision of excess skin and f
10	Marking and incision of new position for the umbilicus
11	Closure of lower abdominal incision and inset of umbilicus
12	Application of dressings and abdominal bind

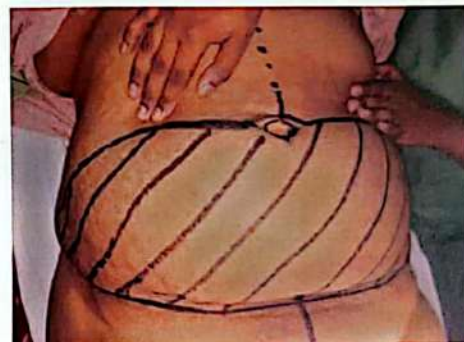

Figure 2: Preoperative Marking

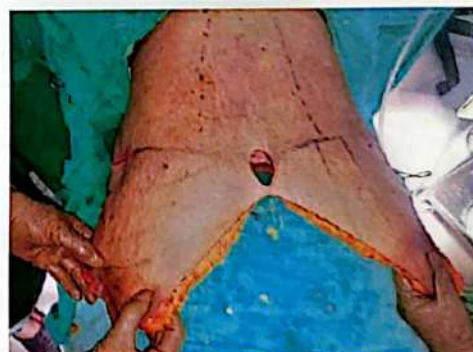

Figure 3: Excess skin flap pulled down after detaching bilicus

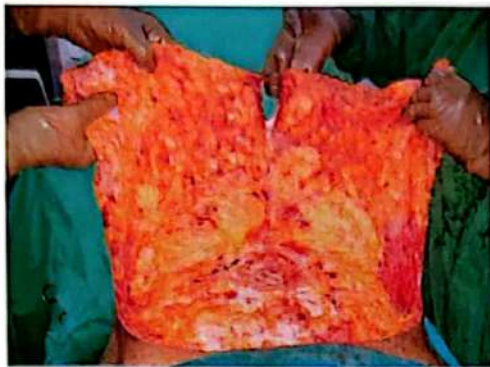

Figure 4: Extent of supra umbilical dissection

Complications

Complications were minimal and insignificant. Out of 47 lipoabdominoplasty cases 4 developed seroma. They were treated by needle aspiration; and none required reoperation. One patient in whom drain was used developed minor wound dehiscence; and it was repaired under local anesthesia. None of the patients had hematoma or infection. There was also no evidence of flap necrosis in any of the patients. (Table 3).

Table 3

Complications (n = 47)	Total
Hematoma	0
Seroma	4
Infection	0
Wound Dehiscence	1
Flap Necrosis	0

Discussion

The etiology of seroma formation following abdominoplasty is multifactorial⁸. Multiple strategies are employed to reduce this complication. Highlighted strategies include preservation of sub-Scarpal fat⁹, limited undermining of the abdominal flap and quilting sutures.

Preservation of sub-Scarpal fat may help obliteration of dead space and help adherence of the abdominal flap to the musculoaponeurotic abdominal wall. This strategy aims to reduce seroma formation through obliteration of dead space and prevention of shearing between the abdominoplasty flap and musculoaponeurotic abdominal wall.

It is important to combine liposuction of upper abdomen and waist area of the abdominoplasty procedure, to ensure adequate postoperative flattening of the abdominal contour¹⁰.

Patients of BMI over 35 can also undergo drainless lipoabdominoplasty¹¹. Post bariatric lipoabdominoplasty patients can also undergo drainless, without any additional risk of seroma formation. In 2018 Medha Anand Bhawe Published a series of 204 cases done in 10 years, with only 1 case of seroma¹ in the Indian journal of plastic surgery.

Even though most of the plastic surgeons around the globe are still using drains in every case, we have stopped using drains in lipoabdominoplasty operations. In our practice, we use drains only if it is absolutely indicated. Since we know the factors that contribute in seroma formation, it is important to focus on modifications of dissection technique, preservation of fascia Scarpa and other technical details in the steps of operation. It has been shown in multiple publications that paying attention to these modifications can significantly reduce the incidence of seroma.

Even if seroma forms, it can very easily treated by aspiration in the office setup. The procedure is painless, and patients hardly ever complain of the needle prick. It may have to be repeated 3 to 7 days later, but it is never a big deal for the surgeon or the patient.

We know that seromas form typically around 2 weeks after the surgery¹². So, its futile to think that seromas can be prevented by the use of drains.

Conclusion

We found that sparing the infraumbilical fascia Scarpa during dissection along with wound closure without tension and avoidance of gliding surfaces with the use of quilting sutures can help avoid the use of drain in lipoabdominoplasty operations. Continuous use of pressure garment in the post operative period is also an important factor in avoidance of seroma formation. Avoiding drains permit early ambulation. And patient comfort is significantly better especially when they are released home on the next day of surgery.

References

1. Bhawe, Medha Anand (Khair). "Can drains be avoided in lipo-abdominoplasty?" Indian Journal of plastic surgery: official publication of the Association of Plastic Surgeons of India vol. 51,1 (2018): 15-23. doi:10.4103/ijps.IJPS_23_18.

2. Seretis K, Goulis D, Demiri EC, et al. "Prevention of seroma formation following abdominoplasty: a systematic review and meta-analysis." *Aesthet Surg J.* 2017;37:316-323. -447.
3. Kathryn V. Isaac, Frank Lista, Mark P. Mcisaac, Jamil Ahmad, "Drainless Abdominoplasty Using Barbed Progressive Tension Sutures,." *Aesthetic Surgery Journal*, Volume 37, Issue 4, I April 2017, Pages 428-429, <https://doi.org/10.1093/asj/sjw241>.
4. Jabbour S, Awaida C, Mhaweji R, et al. "Does the addition of progressive tension sutures to drains reduce seroma incidence after abdominoplasty?." A systematic review and meta-analysis. *Aesthet Surg J.* 2017;37:440-447.
5. Marwan W. Nasr, MD, Samer F. Jabbour, MD, Rachad I. Mhaweji, MD, Joseph S. Elkhoury, MD, Fadi H. Sleilati, MD : "Effect of Tissue Adhesives on Seroma Incidence after Abdominoplasty." A Systemic Review and Meta-Analysis. *Aesthetic Surgery Journal*, Volume 36, Issue 4, April 2016, Pages 450-458
6. Friedman T, Coon D, Kanbour-Shakir A Michaels J, Rubin JP, "Defining the lymphatic drainage of anterior abdominal wall: an anatomic study." *Plast Reconstr Surg* 2015;135:1027-32.
7. Ibrahim M, et al. *Dimens Crit Care Nurs.* 2015 Sep-Oct. Review Article. "Effect of Compression devices on preventing Deep Vein thrombosis among adult trauma patients."
8. Costa-Ferreira A, Rebelo M, Silva A, et al. "Scarpa fascia preservation during abdominoplasty: randomized clinical study of efficacy and safety." *Plast Reconstr Surg.* 2013;131:644-651.
9. Tourani SS, Taylor GI, Ashton MW. "Scarpa fascia preservation in abdominoplasty; Does it preserve the lymphatics? " *Plast Reconstr Surg.* 2015; 136:258-62.
10. Matarasso A. "Liposuction as an adjunct to a full abdominoplasty revisited." *Plast Reconstr surg.* 2000; 106:1197 - 102.discussion 1203-5. (PubMed).
11. Batac J, Hamade M, Hamade H, Glickman L. "Abdominoplasty in the Obese Patient." *Plastic and Reconstructive Surgery*, 2019; 143 (4): 72le
DOI: 10.1097/PRS.0000000000005413.
12. Ricardo Baroudi, MD. Carlos Albarto, Affonso Ferreira, MD. Seroma: "How to avoid it and How to Treat It." *Aesthetic surgery journal*, v 18, Issue 6, Nov 1998, pages 439-441.

Copyright © 2020, Bangladesh Society of Aesthetic Plastic Surgeons. This is an open-access article distributed under the terms of the Creative Commons Attribution 4.0 International license.

Received: 05 Sept. 2019

Accepted: 10 Nov. 2019

PDF Downloaded use this QR code→

