

## Original Article

## Breast Augmentation Using Implant Placement in Subfascial Pocket: Our Initial Experience

Md. Shariful Islam<sup>1</sup>, Sayeed Ahmed Siddiky<sup>2</sup>, Thrina Islam<sup>3</sup>

### Abstract:

**Introduction:** Breast augmentation also called augmentation mammoplasty is used to increase breast size usually by using silicone implants. It involves placing breast implants under the breast tissue or chest muscle. Subfascial breast augmentation was pioneered by Dr. Ruth Graf in Brazil. There are studies which indicates that sub facial breast augmentation is better than the other techniques commonly used. Regular silicone breast implants are the most popularly used by the plastic surgeons, as they feel and look more real and natural.

**Aim of the study:** The aim of the study was to evaluate the outcome of the subfascial breast augmentation surgery with silicone implants.

**Methods:** It is a retrospective study that was conducted with 15 patients enrolled in the department of Plastic & Aesthetic surgery from January 2018 to January 2021.

**Result:** Among the study population (N=15), the mean age of the samples was 28.67±SD, and the maximum and the minimum age of the study population were 36 and 18 respectively. Four study population 4(26.67%) were actresses and models, One-fifth of the study population 3(20%) were housewives, one-fourth 4(26.67%) of the study population were jobholders, and four 4(26.67%) were students. 80% of the study population underwent this surgery to improve body image and the rest of 20% of the study population were keen on breast augmentation surgery to improve their self-confidence. No complication was observed during the postoperative period and follow-up at three month, six months and at 1 year.

**Conclusion:** Subfascial breast augmentation provides natural results with adequate implant coverage, especially in the upper pole. So, palpability and visibility is minimized; and animation movement of the implant can be avoided. The morbidity and pain associated with the procedure is minimal and the recovery is rapid.

**Keywords:** Peri-areolar Breast Augmentation, Breast enlargement

### Introduction:

Breast augmentation, also known as augmentation mammoplasty, is a surgical

1. FCPS, Plastic & Aesthetic Surgeon, Shahid Ziaur Rahman Medical College, Bogura,
2. FCPS, FRCS, FACS, Consultant Plastic & Aesthetic Surgeon, Institute: Cosmetic Surgery Centre Ltd. & Bangladesh Specialized Hospital Ltd. Dhaka,
3. Coordinator (Research and Training), International Online Journal Hub

#### Correspondence to:

Muhammed Shariful Islam FCPS, Plastic & Aesthetic Surgeon, Shahid Ziaur Rahman Medical College, Bogura, Cell: 01712002891, Email: abrarwadi@gmail.com

procedure where breast implants are inserted beneath the breast tissue/chest muscle to improve breast size. Breast augmentation is a technique for most women to increase their confidence<sup>1</sup>. There are various types of breast implants, such as gel implants and saline implants. They can be round or anatomical depending on the shape. Based on the profile they can be either low profile, medium or high profile. According to the surface, the implants are smooth, textured or micro textured<sup>2</sup>. Reasons why women want breast implants includes boosting in their self-esteem by increasing the size of disproportionally small breasts, when one breast is larger than the other,

and women who had a mastectomy. Breast augmentation surgery involves surgically inserting an implant behind each breast<sup>3</sup>. Breast augmentation is a major positive step for most women. Studies have shown that breast implants can help boost self-esteem, body image, and marital harmony<sup>4</sup>. Subfascial augmentation is a method originally developed to minimize the risk of capsular contracture, and decrease the postoperative pain which is sometimes associated with sub-pectoral augmentation<sup>5</sup>. Subfascial breast augmentation was pioneered in Brazil by Dr. Ruth Graf in 1998 and currently, this procedure has earned interest in the aesthetic world<sup>6</sup>. Breast implant surgery was commenced in Bangladesh in September 2001<sup>7</sup>. In subglandular augmentation the implant is positioned between the Pectoralis Major and glandular tissue of the breast<sup>8</sup>. When the fan-shaped Pectoralis major muscle is divided inferiorly along the ribs, and the implant placed underneath, it is known as sub-pectoral implant<sup>9</sup>. There are some statistical differences between subfascial and subpectoral/subglandular implant placement in terms of breast shape and contour, capsular contracture, implant base and the appearance of folds. Studies show subfascial breast augmentation to be better than subglandular breast augmentation<sup>10</sup>. Recent development in technique and implant quality has contributed to more natural looking results<sup>11</sup>. Silicone gel breast implants are preferred among plastic surgeons rather than saline implants due to better availability and cost difference<sup>12</sup>. The most commonly employed incision for breast implant insertion is the infra-mammary incision. It can also be inserted through a peri-areolar incision. The incision is small and inconspicuous in this location<sup>13</sup>. More than 2 million women have received breast implants in the United States over the past 30 years. Nearly 20% of breast implants are used for reconstruction in breast cancer patients following mastectomy<sup>14</sup>. Some of the complications that may arise after breast augmentation, include breast pain, changes in the nipple and breast sensation, infection, capsular contracture, implant displacement, implant rupture and connective tissue disease<sup>15</sup>. Recently ALCL (Anaplastic Large Cell Lymphoma) has

been linked to breast implant surgery on very rare occasions. In the United States, women of all ages mostly 18 to 70 years do breast augmentation. The average patient age undergoing breast augmentation is 35 to 50 years<sup>16</sup>. Due to skepticism and unawareness breast augmentation was not very commonly performed in Bangladesh before. However, the popularity of breast implant surgery is increasing rapidly<sup>17</sup>. The aim of the study was to investigate the outcome of subfascial placement of breast implant for augmentation, rather than the more traditional submuscular or subglandular placement.

## Methods:

A retrospective cross-sectional study was carried out in the Bangladesh Specialized Hospital and Cosmetic Surgery Centre Ltd during the period from January 2018 to January 2021. A total of 15 patients (N=15) over the period of three years were enrolled in this study following the inclusive criteria. Data were collected using the predesigned semi-structured questionnaire. All patients underwent sub-fascial breast augmentation surgery with the silicone implant. Patients were followed-up at one month, at the sixth month, at 1st year, at 2nd year and at 3<sup>rd</sup> year. Eight patients completed their three years follow-up, four patients completed their follow-up at 2nd year. Furthermore, one and two patients completed their one-year follow-up and at the three-month follow-up after surgery. All the patients recovered smoothly. Most of the patients return to normal office work within one week of surgery. None of the cases developed capsular contracture. There was no distortion of the implant. Verbal consent was taken before recruiting the study population. The information was kept confidential only to be used for the study purpose.

### Inclusion criteria:

Patients who underwent breast augmentation surgery for aesthetic purposes.

### Exclusion Criteria:

Patients who underwent reconstruction following mastectomy due to malignancy or prophylactic mastectomy.

Patients who showed unwillingness to participate

in the study.

#### Data analysis:

Random checks were done to ensure that data collection procedures were followed. Completed data forms were examined, amended, and processed for computer data input. Frequencies and percentages were used for descriptive analysis. The data analysis was performed using Statistical Package for the Social Sciences (SPSS) Version 25.0.

#### Anatomy & Surgical Technique:

Under general anesthesia and supine position, inframammary incision was used. After skin and subcutaneous tissue were divided, the fascia over the pectoralis major muscle was incised. Pectoral fascia is a layer of fibrous tissue over the pectoralis major muscle. The lower portion of the fascia is relatively thin, but gradually becomes thicker superiorly. The fascia can be readily raised from inframammary approach. Raising the fascia from periareolar incision is also possible. A combination of sharp and blunt dissection is used. Diathermy can also be used as required. Dissection is done up to 2nd intercostal space superiorly and medially 2 cm away from the midline, inferiorly 2 cm from the inframammary crease. The implant was then introduced. Closure is done by 2/0 vicryl for deeper tissues and 4/0 vicryl was used for intradermal skin closure. No drain tube was used. Patients were instructed to avoid lifting heavy weight for 4 to 6 weeks.

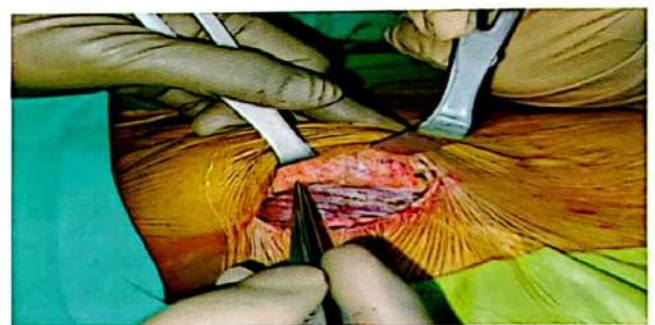
#### Results:

Among the study population (N=15) patients were aged from 18 to 40 years. The mean age of the samples was  $28.67 \pm SD$ , and the maximum and the minimum age of the study population were 40 and 18 respectively. Around two-fifths of the study population (40%) completed higher secondary levels, one patient (6.66%) completed secondary levels, four patients (26.7%) were graduates, one-fifth of the study population (20%) completed Master's degree and only one patient (6.66%) was a doctor. Four patients (26.67%) were actresses and models, one-fifth of the study population (20%) were housewives, one-fourth (26.67%) of the study population were job holders, and four patients (26.67%) were

students. 80% of the study population underwent this surgery to improve body image and the rest of 20% of the study population were keen on breast augmentation surgery to improve their self-confidence.

**Table 1: Characteristics of Study Population (N=15)**

Characteristics	Frequency	
Age	18-40	
	Mean Age $28.67 \pm SD$	
	Minimum Age 18	
	Maximum Age 40	
Education	SSC	1(7%)
	HSC	6(40%)
	Graduate	4(26%)
	Masters	3(20%)
	MBBS	1(7%)
Occupation	Modelling and acting	4(26.67%)
	Job Holder	4(26.67%)
	Student	4(26.67%)
	Housewife	3(20%)
Distribution based on the indication	Improve body image	12(80%)
	Improve self-esteem	3(20%)
Breast size before BA	Mean	breast-size $33.20 \pm SD$
	Minimum	32
	Maximum	36



**Fig 1: Subfascial pocket dissection and fibers of Pectoralis Major muscle (per-operative)**

Mean breast size before breast augmentation was  $33.20 \pm SD$  and the minimum breast size was 32 and the maximum breast size was 36. No

complication was observed during the postoperative period and follow-up at the one month, sixth month, 1st year, 2nd year and at 3rd year follow-up after surgery were recorded. No capsular; contracture, or post-operative wound infections were seen and no animation deformity was reported during the study period.

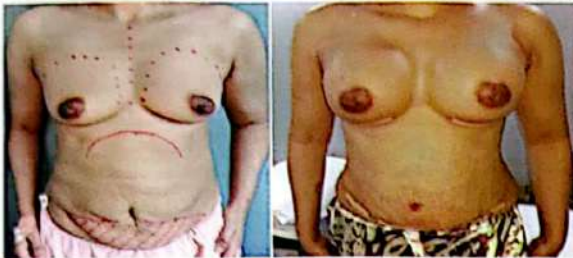

Fig 2: before and after one month of breast augmentation

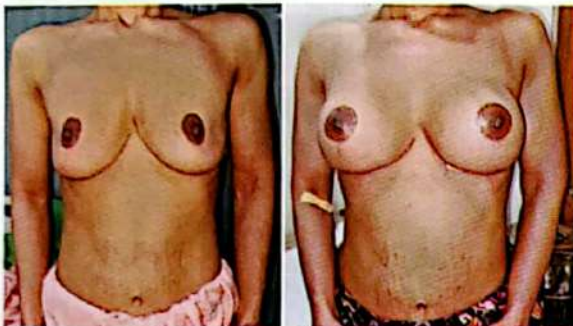

Fig 3: before and after images following subfascial breast augmentation surgery after 6 months.

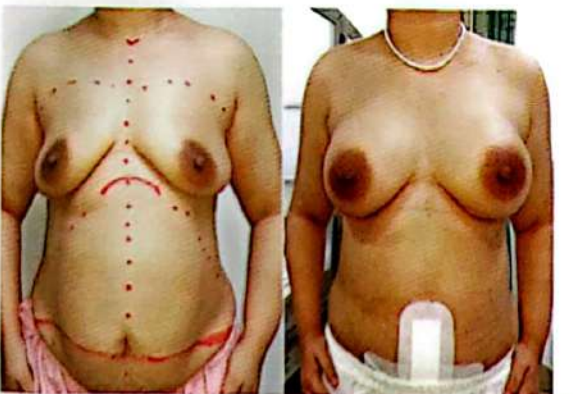


Fig 4: before and after images following subfascial breast augmentation surgery, done as part of "mommy makeover"

### Discussion:

In the current study, all of the study population underwent subfascial breast augmentation surgery. None of the patients (N=15) developed

any complications during the post-operative period and during follow-up. The level of satisfaction was assessed six months after the procedure. During six months after surgery, breast shape continues to change and edema might cause potential volume distortion and asymmetry<sup>18</sup>.

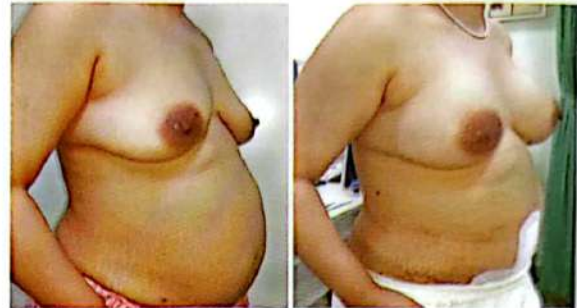

Fig 5: Same patient as in Figure 4 in right oblique view.

Several studies show the sub-muscular placement of implants have animation problems whilst sub-glandular placement confers little coverage especially in small breasts<sup>19,20</sup>. Subfascial placement helps prevent animation problems commonly seen after sub-muscular implant placement. Sub glandular placement has advantages of easier dissection and rapid recovery but it has disadvantages like rippling, upper pole step deformity, inadequate coverage and more prominence of the implant due to superficial placement.

Gould et. al. (2020) found that subfascial breast augmentation surgery has a lower risk of capsular contracture compared with sub-glandular and submuscular breast augmentation. Submuscular implant placement leads to more animation of the implant with muscle contraction during movement of the arm<sup>6</sup>. Different studies suggested that subfascial breast augmentation surgery has fewer complications in comparison with other breast augmentation surgery procedures. It has the advantage of avoiding division of the Pectoralis Major muscle and less post-operative pain due to less tissue dissection<sup>21</sup>. In the present study, only silicone gel implant was used. The latest generation of silicone gel implants and subfascial approaches has enhanced aesthetic outcomes following breast augmentation<sup>22</sup>.

Breast augmentation to enhance the shape and the size of the breasts is well established for restoring and rejuvenating femininity<sup>23</sup>.

Breast augmentation is a well-known procedure and continues to be one of the most frequently performed aesthetic surgeries worldwide<sup>24</sup>. The cardinal characteristic of subfascial breast augmentation is the creation of a strong support system for the implant's upper pole. Displacement in this position is avoided by placing the upper pole between muscle and fascia which constitutes a strong support system compared to sub-glandular approach<sup>25</sup>.

Subfascial breast augmentation was started with a view to lessen the incidence of capsular contracture while at the same time reducing postoperative morbidity related with subpectoral augmentation<sup>26</sup>. Another advantage of Subfascial breast augmentation surgery is the implant remains secured in place and a natural outcome is heightened since the skin and subcutaneous tissue in the upper third of the pocket are not directly in contact with the implant. In case of sub glandular placement, the implant is more prominent due to less coverage and direct contact of the implant with the subcutaneous tissue in the upper part of the breast. Therefore, subfascial breast augmentation technique reduces visibility of the edges of the implant on the skin, making them less prominent. The stronger support system that results from the subfascial placement of the implant prevents the implant's shape and position from altering. Subfascial breast augmentation has distinct benefits as it combines the advantages of the sub-glandular approach like more exact control of both breast shape and inframammary fold positions, more expeditious postoperative recovery, and lack of distortion<sup>27</sup>. Disadvantages of the subpectoral approach such as malposition over time, the tendency for lateral displacement, increased morbidity in case of recovery from pain, and the inframammary fold's malposition have been considerably lessened by using the subfascial technique<sup>28</sup>. The subfascial breast augmentation technique suggests enhanced long-term aesthetic results. This technique is flexible and may also be used in the study population requiring the removal and replacement of breast implants.

## Conclusion:

Precision in surgical technique during breast implant surgery with silicone implants can decrease the risks of complication. Subfascial breast augmentation provides natural looking results, providing adequate implant coverage, thus preventing palpability and visibility of implants. Postoperative pain is less and implant animation during arm movement can be avoided. Overall patient and physician satisfaction are high. Thus subfascial breast augmentation with silicone implant has now become the preferred technique for breast augmentation for many plastic surgeons across the globe.

## Recommendation:

Further research is needed to get robust data to conclude a better aesthetic outcome and study the populations' satisfaction with sub-fascial breast augmentation surgery with silicone implants.

**Funding:** No funding sources

**Conflict of interest:** None declared

**Ethical approval:** The study was approved by the Institutional Ethics Committee

## References:

1. Adams Jr WP, Mallucci P. Breast augmentation. *Plastic and reconstructive surgery*. 2012 Oct 1;130(4):597e-611e.
2. Hidalgo DA, Spector JA. Breast augmentation. *Plastic and Reconstructive Surgery*. 2014 Apr 1;133(4):567e-83e.
3. Papadopoulos N, Totis A, Kiriakidis D, Mavroudis M, Henrich G, Papadopoulos O, Kovacs L, Herschbach P, Machens HG, Biemer E. Quality of life, personality changes, self-esteem, and emotional stability after breast augmentation. *European Journal of Plastic Surgery*. 2014 Sep;37(9):479-88.
4. Figueroa-Haas CL. Effect of breast augmentation mammoplasty on self-esteem and sexuality: a quantitative analysis. *Plastic Surgical Nursing*. 2007 Jan 1;27(1):16-36.

5. Hunstad JP, Webb LS. Subfascial breast augmentation: a comprehensive experience. *Aesthetic plastic surgery*. 2010 Jun;34(3):365-73.
6. Gould DJ, Shauly O, Ohanissian L, Stevens WG. Subfascial breast augmentation: a systematic review and meta-analysis of capsular contracture. *In Aesthetic Surgery Journal Open Forum* 2020 Jan (Vol. 2, No. 1, p. ojaa006). US: Oxford University Press.
7. Siddiky SA, Quader F, Rahman MH. Breast Implant Surgery in Bangladesh: An Experience of 126 cases. *Bangladesh Journal of Plastic Surgery*. 2010;1(2):10-3.
8. Lista F, Tutino R, Khan A, Ahmad J. Subglandular breast augmentation with textured, anatomic, cohesive silicone implants: a review of 440 consecutive patients. *Plastic and reconstructive surgery*. 2013 Aug 1;132(2):295-303.
9. Strasser EJ. Results of subglandular versus subpectoral augmentation over time: One surgeon's observations. *Aesthetic Surgery Journal*. 2006 Jan 1;26(1):45-50.
10. Graf RM, Junior IM, de Paula DR, Ono MC, Urban LA, Freitas RS. Subfascial versus subglandular breast augmentation: a randomized prospective evaluation considering a 5-Year follow-up. *Plastic and Reconstructive Surgery*. 2021 Aug 11;148(4):760-70.
11. Sforza M, Hammond DC, Botti G, Hedén P, ChacónQuirós M, Munhoz AM, Kinney BM, Corduff N. Expert consensus on the use of a new bioengineered, cell-friendly, smooth surface breast implant. *Aesthetic surgery journal*. 2019 Apr 8;39(Supplement\_3):S95-102.
12. Mohebbali K, Wixtrom RN. Breast implant engineering and performance. *Plastic and Reconstructive Surgery*. 2018 Oct 1;142(4S):6S-11S.
13. Kalaaji A, BergsmarkBjertness C, Nordahl C, Olafsen K. Survey of breast implant patients: characteristics, depression rate, and quality of life. *Aesthetic Surgery Journal*. 2013 Feb 1;33(2):252-7
14. Le GM, O'Malley CD, Glaser SL, Lynch CF, Stanford JL, Keegan TH, West DW. Breast implants following mastectomy in women with early-stage breast cancer: prevalence and impact on survival. *Breast Cancer Research*. 2005 Apr;7(2):1-0.
15. Rubino C, Brongo S, Pagliara D, Cuomo R, Abbinante G, Campitiello N, Santanelli F, Chessa D. Infections in breast implants: a review with a focus on developing countries. *The Journal of Infection in Developing Countries*. 2014 Sep 12;8(09):1089-95.
16. Coroneos CJ, Selber JC, Offodile AC, Butler CE, Clemens MW. US FDA breast implant postapproval studies: long-term outcomes in 99,993 patients. *Annals of surgery*. 2019 Jan 1;269(1):30-6.
17. Nizum NA. A Study on Breast Cancer Awareness and Knowledge among Rural Female Population of Bangladesh (Doctoral dissertation, East West University).
18. Alderman AK, Bauer J, Fardo D, Abrahamse P, Pusic A. Understanding the effect of breast augmentation on quality of life: prospective analysis using the BREAST-Q. *Plastic and reconstructive surgery*. 2014 Apr 1;133(4):787-95.
19. Junior IM, Graf RM, Ascenço AS, Itikawa W, Balbinot P, Munhoz AM, Lopes MC, Nasser IJ, Urban LA, da Silva Freitas R. Is there a breast augmentation outcome difference between subfascial and subglandular implant placement? A prospective randomized double-blinded study. *Aesthetic Plastic Surgery*. 2019 Dec;43(6):1429-36.
20. Lee JH, Lee PK, Oh DY, Rhie JW, Ahn ST. Subpectoral-subfascial breast augmentation for thin-skinned study population. *Aesthetic plastic surgery*. 2012 Feb;36(1):115-21.
21. Egeberg A, Sørensen JA. The impact of breast implant location on the risk of capsular contraction. *Annals of plastic surgery*. 2016 Aug 1;77(2):255-9.
22. Goes JC, Munhoz AM, Gemperli R. The subfascial approach to primary and secondary breast augmentation with autologous fat grafting and form-stable implants. *Clinics in Plastic Surgery*. 2015 Oct 1;42(4):551-64.
23. Hopner V, Chamberlain K. Commodifying femininity: The on-line offering of breast augmentation to New Zealand women. *Journal of Gender Studies*. 2020 Aug 17;29(6):651-63.
24. American Society of Plastic Surgeons. 2013 cosmetic plastic surgery statistics. Available at: <http://www.plasticsurgery.org/news/plastic-surgerystatistics/2013.html>. [Last Accessed: 7-5-2022].
25. Pereira LH, Sterodimas A. Transaxillary breast augmentation: a prospective comparison of subglandular, subfascial, and submuscular implant insertion. *Aesthetic plastic surgery*. 2009 Sep;33(5):752-9.
26. Gould DJ, Shauly O, Ohanissian L, Stevens WG. Subfascial Breast Augmentation: A Systematic Review and Meta-Analysis of Capsular Contracture. *Aesthet Surg J Open Forum*. 2020 Feb 5;2(1):ojaa006. doi: 10.1093/asjof/ojaa006. PMID: 33791626; PMCID: PMC7671235.

27. Brown M. Invited Discussion on: Subfascial Breast Augmentation with Crossed Fascial Sling, Under Tumescant Anesthesia with or Without Sedation and Lower Periareolar Access. *Aesthetic Plastic Surgery*. 2020 Oct;44(5):1514-5.
28. Junior IM, Graf RM, Ascenço AS, Itikawa W, Balbinot P, Munhoz AM, Lopes MC, Nasser IJ, Urban LA, da Silva Freitas R. Is there a breast augmentation outcome difference between subfascial and subglandular implant placement? A prospective randomized double-blinded study. *Aesthetic Plastic Surgery*. 2019 Dec;43(6):1429-36.

**Copyright** © 2021, Bangladesh Society of Aesthetic Plastic Surgeons. This is an open-access article distributed under the terms of the Creative Commons Attribution 4.0 International license.

**Received:** 04 Nov. 2021

**Accepted:** 08 Dec. 2021

PDF Downloaded use this QR code→

